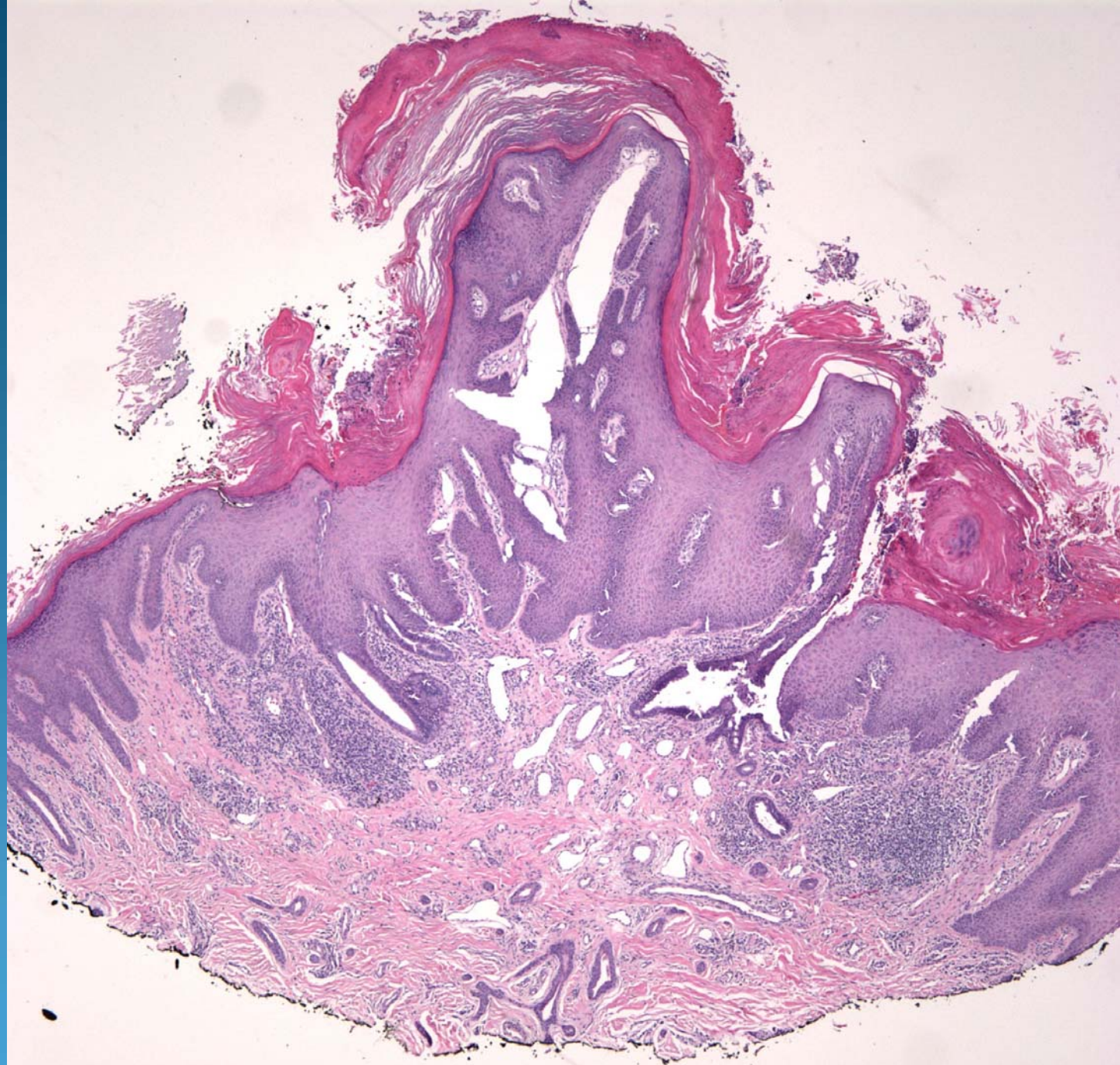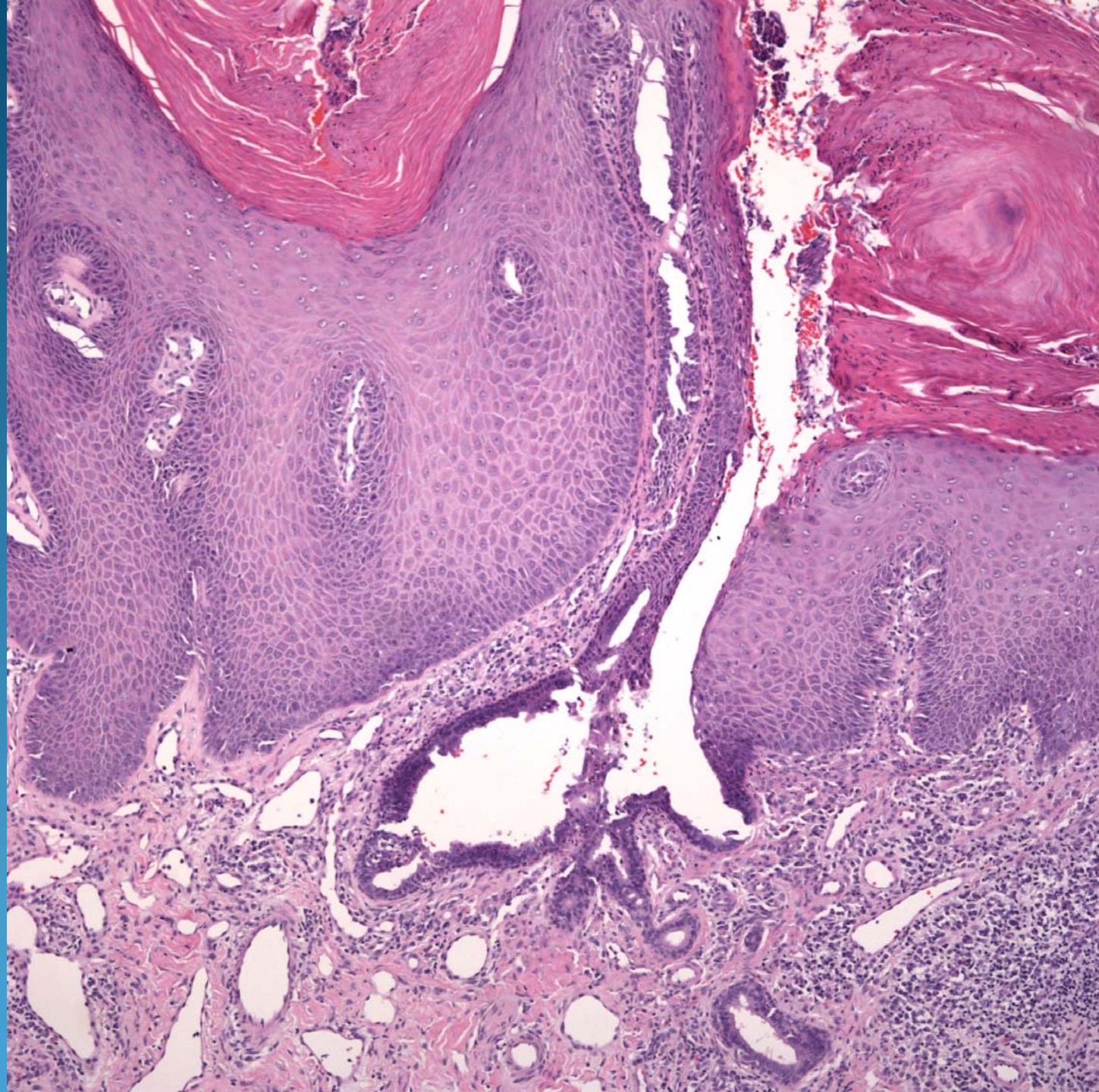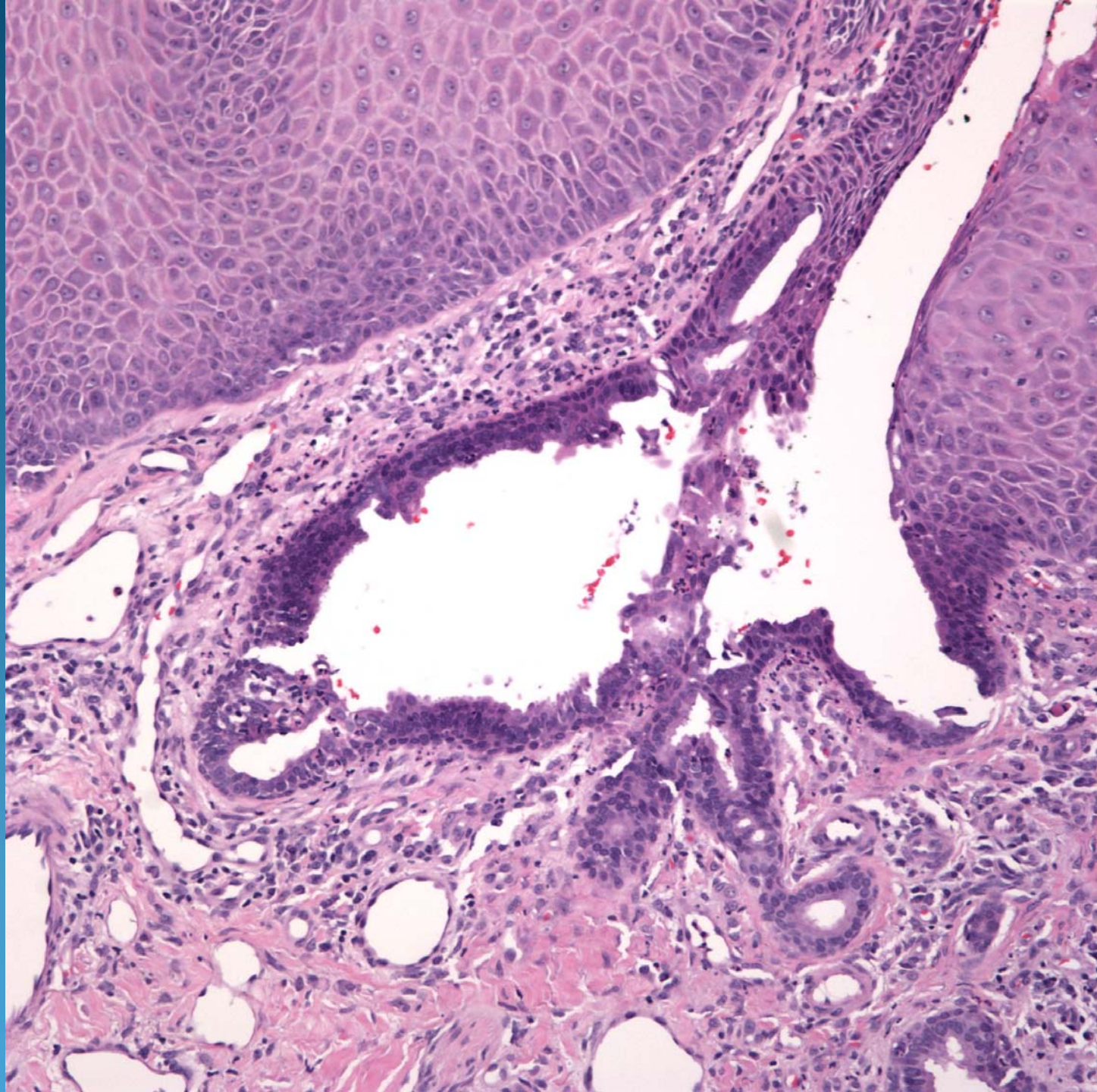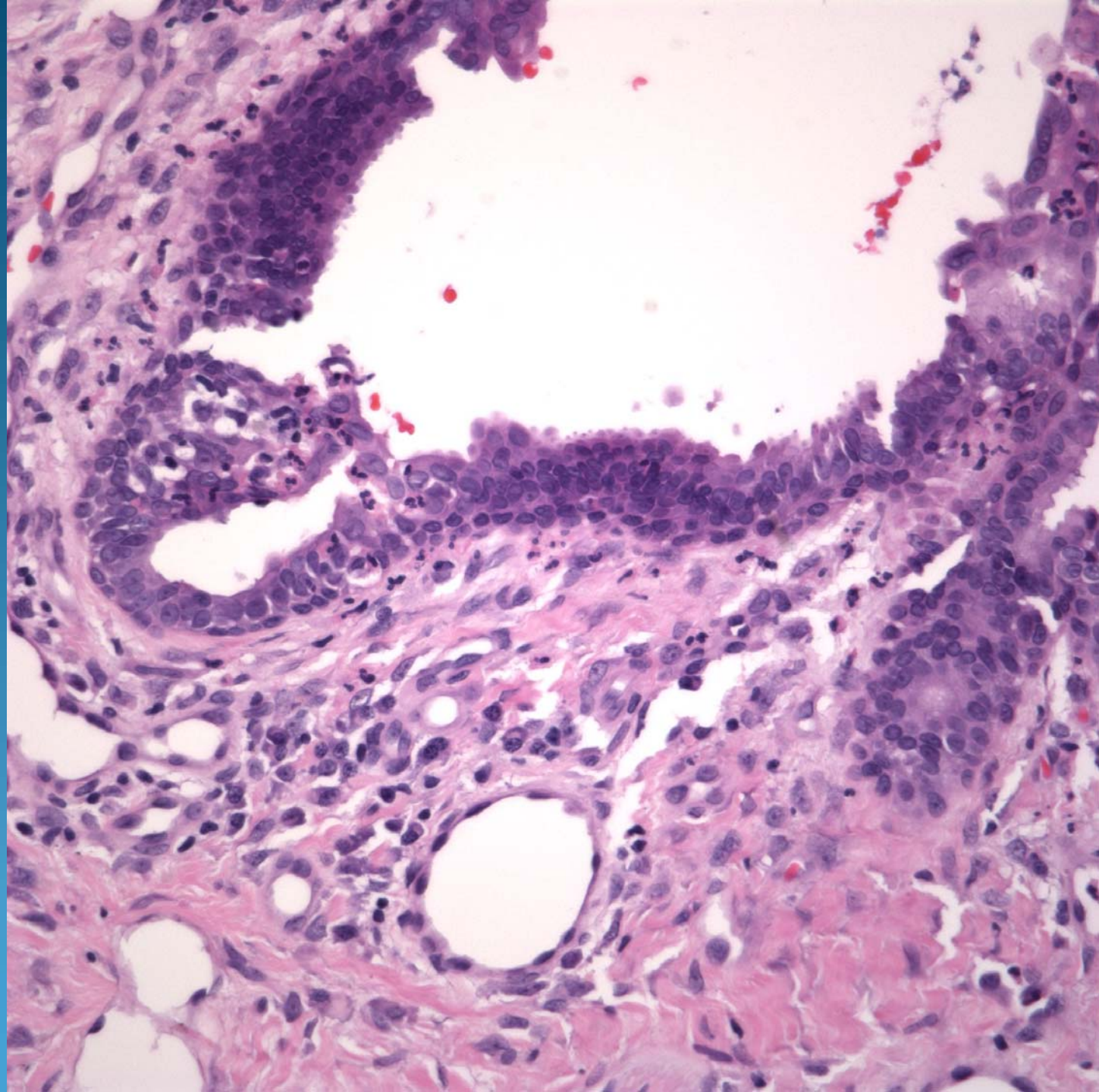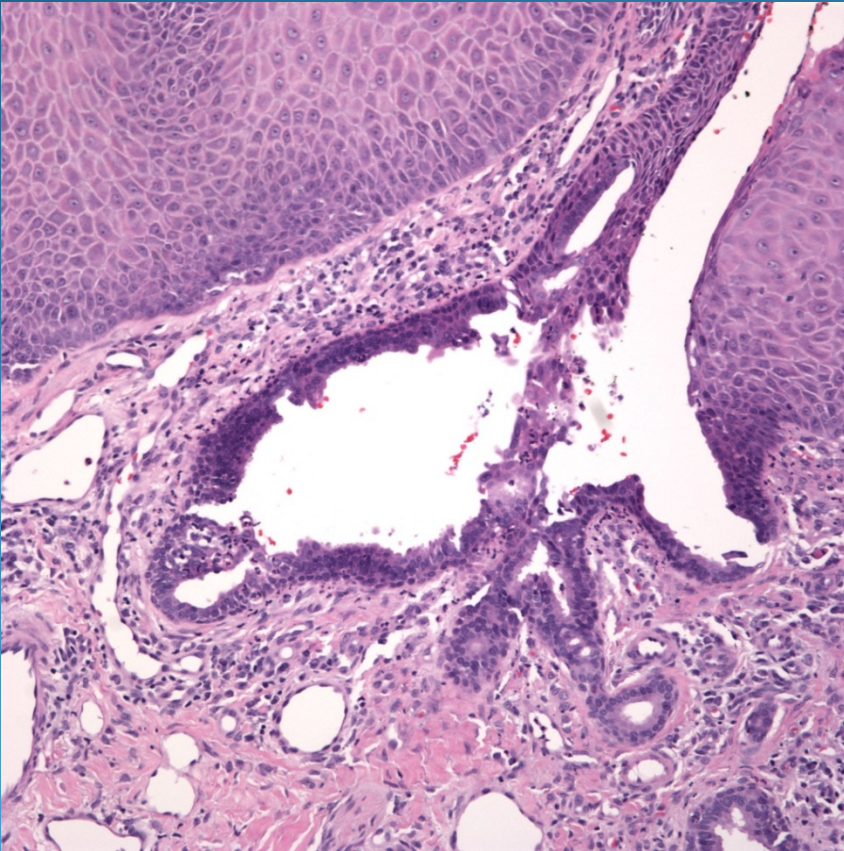


# Syringocystadenoma Papilliferum

# Pearls



- Downward invagination of epidermis forming cystic spaces
- Cyst lined by apocrine epithelium
- Cyst surrounds numerous mature plasma cells